

# SAFE ABDOMINOPLASTY IN AN OFFICE SETTING: THE MODIFIED AVELAR TECHNIQUE

by Peter Lisborg, MD; Matthias Sandhofer, MD; and Guillermo Blugerman, MD

## Complication versus success

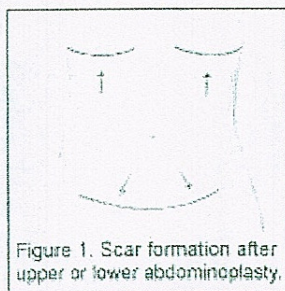


Figure 1. Scar formation after upper or lower abdominoplasty.

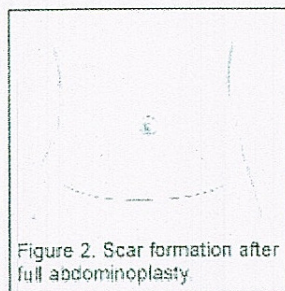


Figure 2. Scar formation after full abdominoplasty.

Tummy tuck, or abdominoplasty, is the sixth most frequently requested cosmetic procedure. More than 100,000 abdominoplasty surgeries were performed in the United States alone during the year 2003<sup>1</sup>. Although this procedure is becoming more popular, classical abdominoplasty is related to a relatively high complication rate. According to a national survey, postoperative mortality in a national survey was 0.2% in 1977<sup>2</sup> and decreased to 0.04% by 1989 (Figure 3). Although major complications have diminished in recent decades, wound complication rates remain high—up to 30%.<sup>3,4,5,6</sup>

During the 1990s, the combination of liposuction and abdominoplasty gained much popularity.<sup>7,8,9,10</sup> The increased use of tumescent anesthesia in particular, enabled the procedure to be performed ambulatory—often in a physician's office setting.<sup>11,12, 13,14,15</sup> Despite these developments, wound complications such as seromas, dehiscence and necrosis still remained high.<sup>9,10,11</sup>

Juarez Avelar, MD, postulated that large-scale undermining of the abdominal flap involving the rupture of the lymphatic and perforator blood supply caused wound complications. To reduce these complications, he developed a new surgical technique that avoids wide undermining, which he presented at the 36th Brazilian Congress of Plastic Surgery in 1999.<sup>16</sup> Blugerman then modified this specific technique to include the use of tumescent anesthesia.<sup>17</sup> The purpose of this article is to demonstrate the safety and effectiveness of this new abdominoplasty concept.

## Patients and Methods

Between April 2002 and December 2004, 71 patients underwent surgery to remove excess abdominal skin and fat. All of these patients had surgery in well-equipped office facilities on an outpatient basis. Of those patients, 97% were female and ranged in age between 20 and 82; the average age was 47.

Indications for abdominoplasty were localized adiposities with flaccid, poor-quality skin. According to the patient's needs, upper or lower abdominoplasty (Figure 1) or full abdominoplasty with umbilicus transposition (Figure 2) was performed. Ptosis of



the pubic region was evaluated and taken into consideration during the preoperative marking for lower and full abdominoplasty. The postoperative elevation of ptotic pubic tissue will otherwise result in a highly placed scar.

Patients were premedicated with 3–5 mg of midazolam and were locally infiltrated with 0.05–0.1% of tumescent solution (lidocaine, epinephrine, and sodium bicarbonate). The concentration and volume of tumescent solution was adapted to allow maximal volume infiltration of the treated areas and did not exceed 50 mg lidocaine/kg.




Figure 3. Preservation of subcutaneous structures.

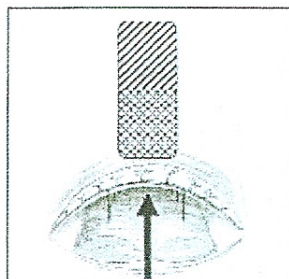


Figure 4. Extent of undermining for umbilicus transposition, and repair of rectus diastasis with preservation of paramedian perforators.



Figure 5. Undermining in the median plane.

Before & After

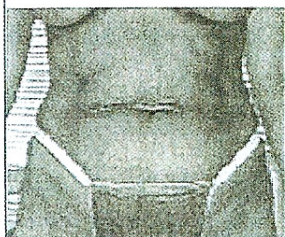


Figure 6. Frontal view before upper abdominoplasty.

Before & After

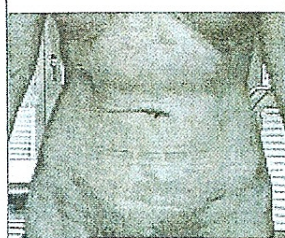


Figure 7. Two months post operative.

Before & After

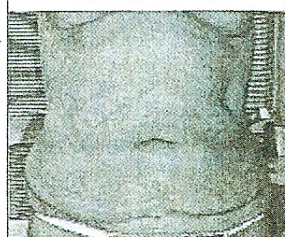


Figure 8. Patient with CHE scar before full abdominoplasty.

Before & After



Figure 9. One day post operative.

Before & After

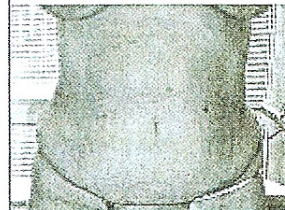
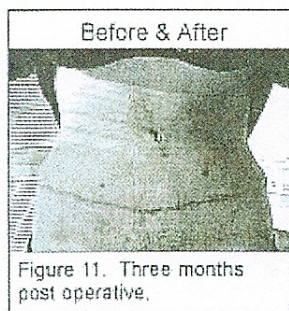



Figure 10. Frontal view before full abdominoplasty.



## The Aid of Liposuction



Liposuction with powered cannula (PAL) was then performed on the entire abdominal region, starting in the deep and ending in the superficial levels. Under the skin to be resected, a radical liposuction was performed to remove as much fatty tissue as possible. After inspection with the patient in a standing position, a superficial skin resection was performed.



Caution was given to specifically resect only the dermis and preserve the subcutaneous structures (Figure 3). In the umbilicus transformation (full abdominoplasty) cases, undermining was performed restrictively and only in the medial plane to preserve the paramedian perforating neurovascular bundles (Figures 4 and 5) and to enable umbilicus reimplantation. In cases with rectus diastasis, the undermining of the median plane was continued superiorly until the xiphoid. When necessary, small amounts of tumescent solution were infiltrated under the rectus fascia, enabling the diastasis to be closed with strong nylon sutures under direct vision.



Wound closure was performed directly, without further undermining, by folding over the subcutaneous structures. No drains were used. Patients were mobilized immediately after the operation and then given nonsteroid antiphlogistica to control their postoperative pain.

## Results and Follow-Up



The extent of abdominoplasty is listed in Table 1. Seven patients underwent full abdominoplasty to correct rectus diastasis. In these cases, hospital admission was not required, skin necrosis did not result, and no seromas were aspirated. One patient developed a suture fistula with a resulting wound dehiscence (4 cm diameter), and achieved secondary healing under ambulatory care. Two patients reported prolonged pain (more than one week), and only one patient required more than one week to resume normal activity.

Subsequent cosmetic procedures were performed on 53 of the 71 patients (75%). Of the remaining 18 patients, six stated they were very happy with the result, seven stated they were happy with the result, and five stated that the follow-up period was too short. In consideration of the fact that many patients returned for other cosmetic procedures, it has to be assumed that overall they were satisfied with their abdominoplasties—a total satisfaction rate of 93% (66/71) (Figures 6–13).

## Conclusion



4. Manassa EH, Hertl CH, Olbrisch RR. Wound healing problems in smokers and nonsmokers after 132 abdominoplasties. *Plast Reconstr Surg.* 2003;111(6): 2082-2089.
5. Hensel JM, Lehman JA Jr, Tantri MP, Parker MG, Wagner DS, Topham NS. An outcomes analysis and satisfaction survey of 199 consecutive abdominoplasties. *Ann Plast Surg.* 2001;46(4):357-363.
6. Chaouat M, Levan P, Lalanne B, Buisson T, Nicolau P, Mimoun M. Abdominal dermolipectomies: early postoperative complications and long-term unfavorable results. *Plast Reconstr Surg.* 2000;106(7): 1614-1618.
7. Matarasso A. Abdominoplasty: a system of classification and treatment for combined abdominoplasty and suction-assisted lipectomy. *Aesthetic Plast Surg.* 1991;15(2):111-121.
8. Shestak KC. Marriage abdominoplasty expands the mini-abdominoplasty concept. *Plast Reconstr Surg.* 1999;103(3):1020-1035.
9. Cardenas-Camarena L, Gonzalez LE. Large-volume liposuction and extensive abdominoplasty: a feasible alternative for improving body shape. *Plast Reconstr Surg.* 1998;102(5):1698-1707.
10. Dillerud E. Abdominoplasty combined with suction lipoplasty: a study of complications, revisions, and risk factors in 487 cases. *Ann Plast Surg.* 1990;25(5):333-343.
11. Kryger ZB, Fine NA, Mustoe TA. The outcome of abdominoplasty performed under conscious sedation: six-year experience in 153 consecutive cases. *Plast Reconstr Surg.* 2004;113(6):1807-1817.
12. Namias A, Kaplan B. *Dermatol Surg.* Tumescant anesthesia for dermatologic surgery. *Cosmetic and Noncosmetic Procedures.* 1998;24(7):755-758.
13. Byrd HS, Barton FE, Orenstein HH, Rohrich RJ, Burns AJ, Hobar PC, Haydon MS. Safety and efficacy in an accredited outpatient plastic surgery facility: a review of 5316 consecutive cases. *Plast Reconstr Surg.* 2003;112(2): 636-646.
14. Cochran TA. Abdominal lipectomy as an office procedure. *J Med Assoc Ga.* 1991;80(11):631-633.
15. Abramson DL. Tumescant abdominoplasty: an ambulatory office procedure. *Aesthetic Plast Surg.* 1998;22(6):404-407.
16. Avelar JM. A new technique for abdominoplasty-closed vascular system of subdermal flap folded over itself combined with liposuction. *Revista Brasileira de Cirurgia* 1999;88/89:3-20.

17. Blugerman G. Modified abdominoplasty, a new South American technique. Vortrag auf dem Kongress der Deutschen Gesellschaft für Ästhetische Chirurgie, Heidelberg 2002.
18. Matarasso A. Abdominal dermolipectomies: early postoperative complications and long-term unfavourable results (Discussion). *Plast Reconstr Surg.* 2000;106(7):1619-1623.
19. Rosenberg MH, Palaia DA, Bonanno PC. Abdominoplasty with procedural sedation and analgesia. *Ann Plast Surg.* 2001;46(5):485-487.
20. Mayr M, Holm C, Hofter E, Becker A, Pfeiffer U, Muhlbauer W. Effects of aesthetic abdominoplasty on abdominal wall perfusion: a quantitative evaluation. *Plast Reconstr Surg.* 2004;114(6):1586-1594.
21. Farah AB, Nahas FX, Ferreira LM, Mendes Jde A, Juliano Y. Sensibility of the abdomen after abdominoplasty. *Plast Reconstr Surg.* 2004;114(2): 577-583.

**Article Tools**

- » E-Mail This Article
- » Reprint This Article
- » Write the Editor
- » Print This Article