

M. Sandhofer

Zentrum für Haut, Ästhetik, Laser und Venen [Center for Skin, Esthetic, Laser, and Vascular Treatment] in Linz, Austria

Summary:

Stratamed® (by Stratpharma AG) is the first self-drying silicone gel to be approved for use on open wounds and injured skin. A prospective study involving 105 patients examined its effectiveness in treatment and prevention of scarring after ablative and semi-ablative procedures, as well as after excisions in esthetic and plastic surgery. The results confirm the oft-described effects of silicone in promoting wound healing. Due to the gel's simple application and the fact that it does not impair esthetics, patient compliance and patient satisfaction were high across the board. No control group was observed. No quantitative statistical evaluation of the study was performed.

Zusammenfassung:

Das Präparat Stratamed® (Stratpharma AG) ist das erste selbsttrocknende Silikongel, das für die Anwendung auf offenen Wunden und verletzter Haut zugelassen ist. In einer prospektiven Anwendungsstudie mit 105 Patienten wurde seine Wirksamkeit bei der Behandlung und Prophylaxe von Narben nach ablativen und semiablativen Verfahren sowie nach In- und Exzisionen in der ästhetischen und plastischen Chirurgie beobachtet. Die Ergebnisse bestätigen die vielfach beschriebene wundheilungsfördernde Wirkung des Silikons. Aufgrund der einfachen und ästhetisch nicht beeinträchtigenden Anwendung des Gels waren Patientencompliance und Patientenzufriedenheit ausnahmslos hoch. Es wurde keine Kontrollgruppe beobachtet. Eine quantitative statistische Auswertung der Studie wurde nicht durchgeführt.

The Use of a Novel Silicone Gel on Open Wounds and Damaged Skin for Prevention of Scarring

The integrity of human skin is disturbed more and more by injury or surgical intervention. The resulting scars can be esthetically displeasing or even disfiguring and can be accompanied by itching, pain, and disturbed sleep. Functional limitations due to deformation contractures are also possible, depending on the area affected and the intensity of the scar formation. The potential psychosocial consequences are depression and impairment of daily living activities and self-esteem, post-traumatic stress disorder, and stigmatization. All of these consequences of abnormal scar formation lead to a more or less reduced quality of life.¹

In addition to the many methods of scar correction, prophylactic methods seem appropriate as an initial approach so that abnormal scar formation can be reduced or completely prevented from the outset.²

The Center for Skin, Esthetic, Laser, and Vascular Treatment has come to specialize in esthetic interventions and employs a series of different dermatological and surgical procedures in its practice. In the

process, the technology in use at the Center has become so advanced and optimized that it has become possible to predict the visual and functional result of an intervention very precisely. As a result of these precise prognoses, the boundary between acceptable and unacceptable results has become finer and finer, both from the patient's perspective as well as from the physician's. This means that the treating physician must not only exercise special care during the procedure, but also must be intensively involved in the healing process and undertake effective and esthetically supportive steps post-op.

The Center's avowed goal to promote the most esthetic, rapid, and functional healing possible requires products that can be used immediately after treatment to prevent scar formation and for general support of wound healing. The treatments performed at the Center include ablative procedures such as laser techniques, dermal abrasion, and chemical peelings, as well as surgical incisions and excisions. One product that meets the Center's requirements is Stratamed's tube-dispensed silicone gel (Strat-

pharma), which forms a self-drying protective sheet. It consists of inert silicone polymers and can be applied directly to open wounds and to areas of skin with weakened integrity. The polymers it contains have no measurable pH value, and therefore do not affect the protective acid mantle of the skin and do not react with the newly forming epithelial tissues. Stratamed is the first self-drying silicone gel that is indicated for prevention and treatment of scars on open wounds and on skin whose integrity has been damaged. It has been approved in Switzerland (CE 1254) and Europe as a Class 2a Medical Device as well as in other countries. This article describes our experiences with this product in 105 patients.

The use of silicone in scar treatment

By the early 1980's, silicone was being used for scar therapy³, especially for treating hypertrophic scars and keloids. Thanks to the good results obtained^{4,5}, this treatment, in the form of silicone gel sheets, rapidly became the standard in plastic surgery.² Its effectiveness when used for scar prevention was also repeatedly confirmed.^{6,7,8} The "International Clinical Recommendations on Scar Management"⁹ thus recommended silicone gel sheets as the first choice for treating and preventing hypertrophic scars and keloids. Further development of silicone technology and the introduction of tube-dispensed self-drying products made it possible to overcome significant disadvantages and application limitations associated with the sheets: It became easier to properly apply the silicone sheet, especially to areas of skin exposed to intensive move-

ments, and the cosmetic appearance was significantly improved, leading to better compliance.⁹ Current clinical studies and published clinical experience show that the air-drying tube-dispensed gel has the same effect regarding promoting wound healing in scar treatment and prevention of abnormal scar formation as the traditional silicone gel sheets.^{8,10,11} Immediately after the thinly applied silicone gel dries (4 to 5 minutes), antibiotic salves, sunblock, or makeup can be applied over it.

How silicone works

The silicone gel is applied to the affected area of the skin in a very thin layer and forms a flexible, protective sheet that is gas permeable but semi-occlusive, that binds to the injured skin, but does not penetrate into the epidermis or dermis.¹² According to the most recent studies, the protective sheet restores the natural barrier function of the epidermis and reduces the transepidermal water loss (TEWL) at the injury site. This water loss and the resulting dehydration are assumed to be critical factors behind excessive production of collagen fibers and thus for the formation of an abnormal scar.⁹

Since semi-occlusive wound dressings without silicone have been shown to be less effective in treating scars,¹³ one can assume that silicone possesses other properties that promote wound healing. In this regard, the results of clinical studies indicate that silicone gel raises the level of the β -FGF fibroblast growth factor. The formation of hypertrophic scar tissue that contains histologically normal fibroblasts is prevented by modu-

Table 1: Absolute Frequency of Diagnoses or Procedures

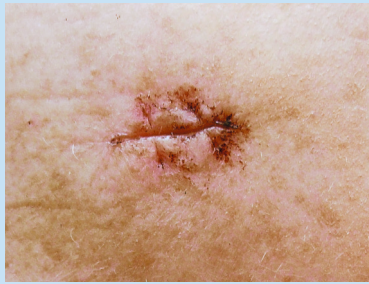Tattoo removal	22
Hypertrophic scars	15
Acne scars	15
Wrinkles	16
Moles	6
Skin tightening (face)	5
Melanoma	4
Keratosis	3
Eyelid surgery	3
Liposuction	3
Venous surgery	2
Trauma wounds	2
Abdominal wall tightening	2
Keloids	2
Basalioma	1
Warts	1
Mammaplasty	1
Rings under eyes	1
Cicatricial alopecia	1
ILVEN	1
Burns	1
Lentigo	1

Table 2: 130 interventions, of which 25 patients in combination therapy

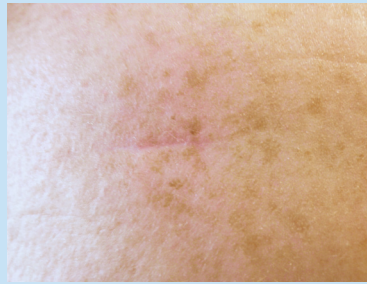
CO ₂ fract. laser (Lutronic)	34
Q-Switch laser	24
1550 fract. laser (Mosaic)	23
Excisions	17
5-FU/triamcinolone injection	16
Fract. radiofrequ. (Intracel-FAKIR)	10
Dermabrasion	4
Cauterization	1
Chemical peeling	1

Table 3: Use of Scar Prophylaxis after Excisions in 17 Patients

Nevus excision	6
Skin tightening (face)	3
Melanoma	3
Eyelid surgery	2
Basalioma	1
Mammaplasty	1
Lentigo	1



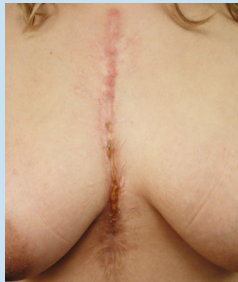Fresh wound post incision



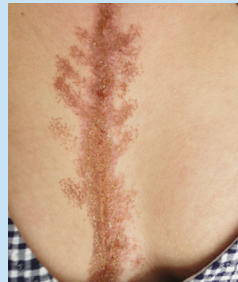Week 8

Figure 1:
Surgical incision

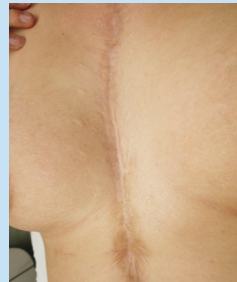Before treatment and 8 weeks post treatment with Stratamed (monotherapy).



Before Treatment



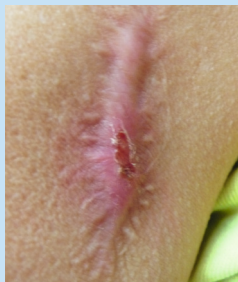
Day 0



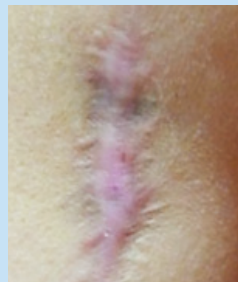Week 10

Figure 2:
Existing hypertrophic scar after thoracic surgery

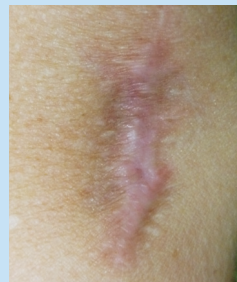
Before, during and 10 weeks post treatment with Stratamed in combination with CO₂/Mosaic fractional laser resurfacing and radio frequency.



Before Treatment



Week 2



Week 7

Figure 3:
Existing hypertrophic scar after excision of a melanoma

Before treatment and after 2 and 7 weeks of treatment with Stratamed in combination therapy with 5-FU/corticosteroid injections.

lating the expression of the growth factors. The data produced so far support the assumption that the property of substances to promote wound healing is based on the fact that they correct an existing shortage or excess of growth hormones that control the repair processes in tissues.¹⁴

Time as a factor in treating wounds with silicone

The knowledge gained from several studies suggests that the time at which a wound is treated has a significant effect on the likelihood of abnormal scar formation.^{15,16,17}

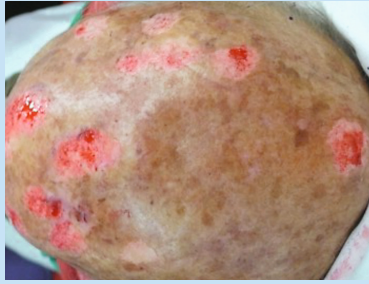
Therefore, the goal should be to achieve the most rapid possible epithelialization of the wound in order to minimize this. This is particularly true for burn wounds and other surface injuries of the epidermis where epithelialization is delayed without additional treatment.

These procedures can be facilitated by the semi-occlusive effect of silicone gel and the accompanying improved tissue hydration of the injured skin area. However, it was previously only possible to use self-drying silicone products when the wound to be treated had already healed and the epithelial formation

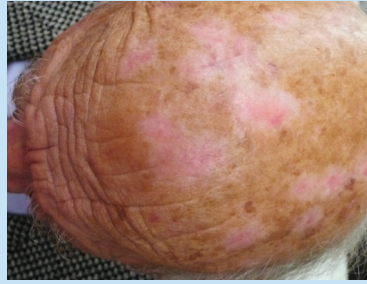was complete, which often delayed the start of treatment by up to several weeks. The silicone preparation Stratamed is therefore particularly well-suited for scar prevention, since it can be used right away at an earlier stage than all the previously available silicone gel products. It is exclusively approved for use on open wounds and skin with damaged integrity.

Patients, materials, and methods

From 2009 to 2010, we monitored 105 patients in a prospective application study at the Zentrum für



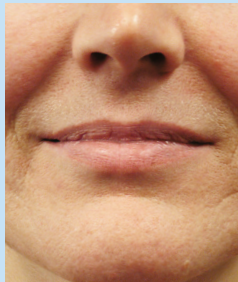Day 0



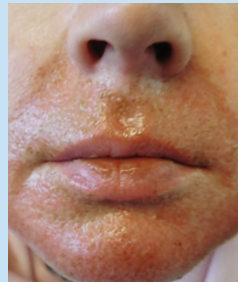Week 4

Figure 4:
Dermabrasion

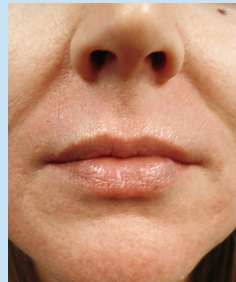During treatment and 4 weeks post treatment with Stratamed (monotherapy).



Before Treatment



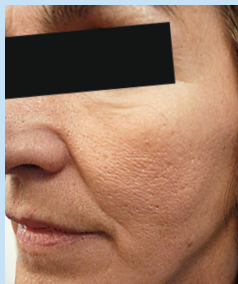Day 0



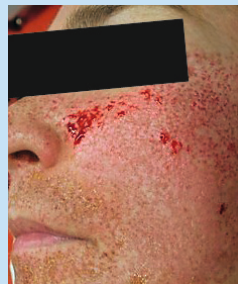Day 10

Figure 5:
Laser resurfacing (wrinkles)

Before, during and 10 days post treatment with Stratamed in combination with thermage, CO₂ fractional laser resurfacing and Botox.



Before Treatment



Day 0



Day 7

Figure 6:
Laser resurfacing (acne scars)

Before, during and 7 days post treatment with Stratamed in combination with thermage and CO₂ fractional laser resurfacing.

Haut, Ästhetik, Laser und Venen in Linz, Austria, following various invasive treatments, and evaluated the effectiveness of Stratamed® (Stratapharma AG, Basel, Switzerland).

Patients enrolled in the study following ablative and semi-ablative laser treatments (fractional CO₂ laser, 1550nm fractional laser, Q-Switch laser 1064), following dermato-surgical and esthetic interventions employing excision, excochleation, dermabrasion, chemical peelings, and patients with existing scars that had been treated with 5-FU/triamcinolone

injections (Tables 1 and 2). These patients included 17 (Table 3) who underwent an excision only, and then had the silicone gel applied immediately after the excision to treat the wound or prevent scarring. Treatment for most patients took place over a period of 2 to 3 months. The patients underwent follow-up during this time and were photographically documented (Figures 1 to 6).

The silicone gel was applied after laser treatments, primarily after CO₂ laser treatments, twice daily, and once daily after the other concomitant treatments. An ointment

with an erythromycin ingredient, preferably with a petroleum base, was applied over the Stratamed for the first two times – particularly after fractional CO₂ laser treatment.

After excision, we generally applied ointments, sometimes with antibiotics, five minutes after applying the silicone gel. No additional scar therapeutics were used. In the case of fresh wounds, excess exudates or fluid from the wound were sponged dry before application. Depending on the skin area or wound to be treated, the silicone gel was used either with or without a protective dressing.

Treatment of existing hypertrophic scars was accompanied with a primary application of the silicone gel, both after 5-FU/triamcinolone injections as well as after the use of fractional lasers or fractional radio frequency systems.

The continued application of the silicone gel after the first application was performed independently by all the patients at home.

Observations and results

The use of Stratamed in the cases of semi-ablative and ablative applications that we monitored significantly reduced susceptibility to inflammation. In fact, in no case did an infection of the wound arise in the area of skin being treated. After ablative and semi-ablative treatments, we were able to observe a very accurate healing of the wound, and no cases of irritation (reddening) occurred here, either. The application of the silicone gel represented a welcome enhancement of the postoperative management process for patients, particularly after excisions: They were able to do the application independently, making additional visits to the physician (except for the mandatory follow-up) unnecessary. Compliance in these cases was 100 percent; all application recommendations were followed without exception.

The patients noted a reduction in feelings of tightness and in reddening. Wound healing was precise, and in only one case did a slight scar hypertrophy occur that made it necessary to perform an injection treatment with 5-FU/triamcinolone. In one case of treatment with a fractional CO₂ laser, a wide-area Herpes eruption occurred;

however, there was no permanent residual scarring after application of the silicone gel in combination with a systemic acyclovir preparation. The visibly faster re-epithelialization that occurred after application of the silicone gel achieved visually satisfactory results for excisions starting about 4 weeks post treatment (Figures 1 to 3), and after as early as 10 days in the case of purely ablative or semi-ablative procedures (Figures 5 and 6).

In those cases where we used ablative or semi-ablative techniques exclusively, we observed a significantly more rapid healing or re-epithelialization with the use of the silicone gel. The protective sheet formed by the silicone gel in these cases was not accompanied by any adhesion to the initially moderate wound granulation. Even after removal of the initial detritus (first day), there was no noticeable abnormal granulation formation. The deposits arising from fractional CO₂ treatment were exfoliated after 3 to 5 days. A significant reduction in reddening, itching, and feelings of tightness was recorded in these cases as well. Moreover, it is noteworthy that the silicone gel proved to be non-disruptive and esthetically tolerable for patients – particularly for facial applications.

Conclusions

Silicone gel has been used in scar treatment for the past 30 years. During this time, the various products have undergone major evolution. Tube-dispensed self-drying silicone gels have in the meantime proven themselves and have become broadly accepted in the field of medicine.⁹ The Stratamed preparation represents an additional ad-

vance, since it is the first silicone gel that has been approved explicitly for use on open wounds and injured skin.

The results of our study show that this new silicone gel is well-suited for treatment of wounds and for use in scar prevention. It was well-suited as a combination therapy with all the procedures used (Table 2). Silicone gel proved particularly helpful in treatment and prevention of scarring when used in combination with fractional systems. We observed that erosive and ablative wounds were better protected than with other procedures we used and that the healing process was supported more strongly. The protective sheet binds with the skin and ensures a consistent and even effect. The result is a favorable environment for the skin healing process, which leads to faster epithelial formation.

In only one case (after excision of a juvenile melanoma in the chest area) did we observe a hypertrophic scar development.

There is no need to adapt existing wound treatment concepts when silicone gel is used, since it is only an add-on. The preparation was well-tolerated without exception and no contact sensitization or infections were observed. In no instance was it necessary to remove the preparation. Patient compliance was high across the board. The factor that contributed to this in particular was the simplicity of application, which could be done by all the patients at home without difficulty.

In order to validate and quantify the results from this initial appli-

cation study with Stratamed, we recommend conducting additional clinical studies with precise measurement data and a control group.

References

1. Bayat, A. et al.: "Skin scarring", *British Medical Journal* 2003; 326:88–92
2. Mustoe, T.A. et al.: "International Clinical Recommendations on Scar Management", *Plastic and Reconstructive Surgery* 2002; 110:560–571
3. Perkins, K. et al.: "Silicone gel: a new treatment for burn scars and contractures", *Burns* 1983; 9:201–204
4. Cruz-Korchin, N.I.: "Effectiveness of Silicone Sheets in the Prevention of Hypertrophic Breast Scars", *Annals of Plastic Surgery* 1996; 437:345–348
5. Ahn, S.T. et al.: "Topical Silicone Gel for the Prevention and Treatment of Hypertrophic Scar", *Archives of Surgery* 1991; 126:499–504
6. Gold, M.H. et al.: "Prevention of Hypertrophic Scars and Keloids by the Prophylactic Use of Topical Silicone Gel Sheets Following a Surgical Procedure in an Office Setting", *Dermatologic Surgery* 2001; 27(7):641–644
7. Borgognoni, L.: "Biological effects of silicone gel sheeting", *Wound Repair* 2002;10(2)118–121
8. Chan, K.Y. et al.: "A Randomized, Placebo-Controlled, Double-Blind, Prospective Clinical Trial of Silicone Gel in Prevention of Hypertrophic Scar Development in Median Sternotomy Wound" *Plastic and Reconstructive Surgery* 2005; 116(4):1013–1022
9. Mustoe, T.A.: "Evolution of Silicone Therapy and Mechanism of Action in Scar Management", *Aesthetic Plastic Surgery* 2008; 32:82–92
10. Signorini, M., Clementoni, M.T.: "Clinical Evaluation of a New Self-Drying Silicone Gel in the Treatment of Scars: A Preliminary Report", *Aesthetic Plastic Surgery* 2007;31:183–187
11. Tobola, J. et al.: "Silicone gel in prevention and treatment of hypertrophic scars and keloids", *Dermatologia Estetyczna* 2004;6(35)323–328
12. Fulton, J.E.: "Silicone Gel Sheeting for the Prevention and Management of Evolving Hypertrophic and Keloid Scars", *Dermatologic Surgery* 1995; 21:947–951
13. Alexandrina, S.S. et al.: "Silicone Occlusive Treatment of Hypertrophic Scar in the Rabbit Model", *Aesthetic Surgery Journal* 2002; 22:147–153
14. Hanasono, M.M. et al.: "The Effect of Silicone Gel on Basic Fibroblast Growth Factor Levels in Fibroblast Cell Culture", *Archives of Facial Plastic Surgery* 2004; 6:88–93
15. Tandara, A.A., Mustoe, T.A.: "The role of the epidermis in the control of scarring: evidence for mechanism of action for silicone gel", *Journal of Plastic Reconstructive Surgery* 2008; 61:1219–1225
16. Upton, Z., Lynam, E.: "Treatment innovations in hypertrophic and keloid scars", *Wounds International* 2011; 2(1): 7–8
17. Gauglitz, G.G. et al.: "Hypertrophic Scarring and Keloids: Pathomechanisms, Current and Emerging Treatment Strategies", *Molecular Medicine* 2011;17(1–2):113–125